



## Gangrene of Meckel's Diverticulum Secondary to Axial Torsion in a Child: An Unusual Complication

### Bir Çocukta Aksiyel Torsiyona Bağlı Meckel Divertikülünün Gangreni: Nadir Bir Komplikasyon

Axial Torsion of Meckel's Diverticulum

Alev Suzen<sup>1</sup>, Nazile Erturk<sup>2</sup>, Yasar Topal<sup>3</sup>

<sup>1</sup>Department of Pediatric Surgery, Mugla Sıtkı Kocman University Research and Training Hospital,

<sup>2</sup>Department of Pediatric Surgery, Mugla Sıtkı Kocman University, Medical Faculty Hospital,

<sup>3</sup>Department of Pediatrics, Mugla Sıtkı Kocman University, Medical Faculty Hospital, Mugla, Turkey

#### Özet

Meckel Divertikülünün (MD) aksiyel torsiyon ve gangreni sonucu gelişen ince barsak obstrüksiyonu, bu konjenital anomalinin en nadir komplikasyonudur. Literatürde sadece 8 çocuk ve 29 civarında erişkin vaka bildirilmiştir. Olgumuz pediatriye gastroenterit nedeni ile başvuran 2 yaşında bir erkek olgudur. Bir sonraki gün safralı kusma ve kolik tarzı karın ağrısı başladı. Klinik ve laboratuvar bulgular akut intestinal obstrüksiyon veya apendisit lehine idi. Laparatomide divertikülden, bitişik olmayan ince barsak mezenterine uzanan iki peritoneal banda bağlı MD'nin aksiyel torsiyonu ve ince barsakların bantların altından herniasyonu saptandı. MD'nin wedge rezeksiyonu yapıldı. Komplike MD'nin spesifik bir bulgusu yoktur. Preoperatif tanı çok zordur. Erken cerrahi, doğru tanı ve barsağın strangülasyonunu önlemek için önemlidir.

#### Anahtar Kelimeler

Meckel Divertikülü; Aksiyel Torsiyon; Çocuk; Gastroenterit

#### Abstract

Axial torsion and gangrene of Meckel's diverticulum (MD) causing small bowel obstruction is the rarest complication of the congenital anomaly. Only 8 cases in children and approximately 20 cases in adults were found in the literature. Our case is a 2-year-old Caucasian male who presented to our pediatric department with gastroenteritis. The following day bilious vomiting and colicky episodic abdominal pain started. Clinical and laboratory findings were suggestive of acute intestinal obstruction or appendicitis. Exploratory laparotomy suggested that 2 peritoneal bands of diverticulum to the mesentery of non-adjacent small bowel were the cause of axial torsion of MD; herniation of small bowels under the bands were observed. Wedge resection of the MD was performed. Complicated MD has no specific value. The preoperative diagnosis is difficult. Early surgery is important for correct diagnosis and for preventing strangulation and gangrene of the bowel.

#### Keywords

Meckel's Diverticulum; Axial Torsion; Children; Gastroenteritis

DOI: 10.4328/JCAM.4590

Received: 27.04.2016

Accepted: 16.05.2016

Printed: 01.09.2016

J Clin Anal Med 2016;7(5): 717-9

Corresponding Author: Alev Suzen, Department of Pediatric Surgery, Mugla Sıtkı Kocman University Research and Training Hospital, Mugla, Turkey.

GSM: +905052103440 E-Mail: alevsuzen@hotmail.com

## Introduction

Johann Friedrich Meckel first described Meckel's diverticulum (MD) in 1809 as an embryological origin of congenital diverticulum of the mid-gut [1]. MD is caused by failure of closure of the vitelline or omphalo-mesenteric duct occurring during embryonic development [2]. MD has an incidence of 1-2 % in the general population [3]. MD cases are generally asymptomatic and complications are reported in only 2-3 % of cases [4]. The common complications caused by MD are rectal bleeding due to ileal peptic ulceration secondary to ectopic mucosa; intestinal obstruction caused by intussusception, small bowel volvulus around a diverticular band, herniation or tumor formation, and acute inflammation leading to perforation and hemorrhage [1, 2, 4-8].

Axial torsion of MD, an extremely rare complication, refers to being axial around its base [1, 3, 4, 8, 9]. This can occur around attachment of the diverticulum to the umbilicus or to the ileal mesentery or with a free-ended diverticulum around a narrow base. Torsion of MD often causes necrosis and perforation [1, 3, 4].

## Case Report

A 2-year-old Caucasian male presented to our pediatric department with fever, vomiting, and diarrhea. The clinical examination revealed a mild depletion of body fluids and absence of abdominal pain. Laboratory tests were normal. The patient was admitted to the pediatric unit and fluid infusion for gastroenteritis was administered. The following day colicky episodic abdominal pain and bilious vomiting started. The clinic examination revealed abdominal pain with guarding and rebound tenderness on the right side. Rectal examination showed right-sided tenderness with negative stool. An abdominal radiograph revealed air-fluid levels in the projection of the small bowel loops (Figure 1). Abdominal ultrasound examination showed di-

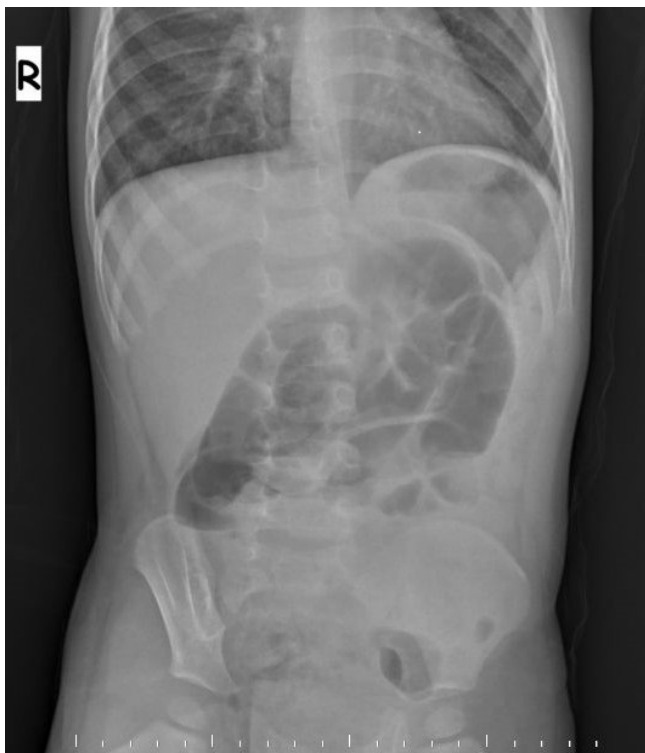

Figure 1. Abdominal radiograph shows air-fluid levels in projection of small bowel loops.

lated small bowel loops with peristalsis partially present, 1 cm diameter non-compressed tubular structure, and some ascites (Figure 2).

The patient was taken for an urgent laparotomy with a clinical diagnosis of acute intestinal obstruction or appendicitis. Intra-operatively there was minimal hemorrhagic fluid and small bowel loops were dilated. Surgical exploration revealed a black axially torsed necrotic MD measuring 3.5 cm in length with a 2 cm base that was located 70 cm proximal to the end of the ileum. Two peritoneal bands which arose from its tip were attached to the mesentery of non-adjacent small bowel and herniation of small bowel segments under a band, caused compression of the ileum resulting in intestinal obstruction (Figures 3,4). The band was lysed, unfolding the bowel and MD. The MD was untwisted and wedge resection was performed. Histological findings confirmed the MD to be necrotic and no ectopic

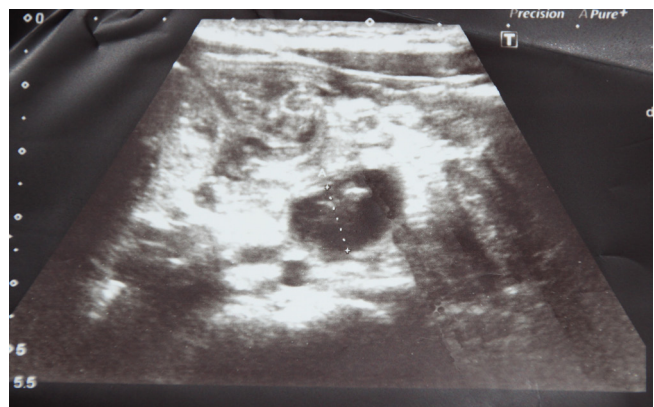


Figure 2. Abdominal ultrasound examination shows dilated small bowel loops with peristalsis partially present, 1 cm diameter non-compressed tubular structure and ascites.

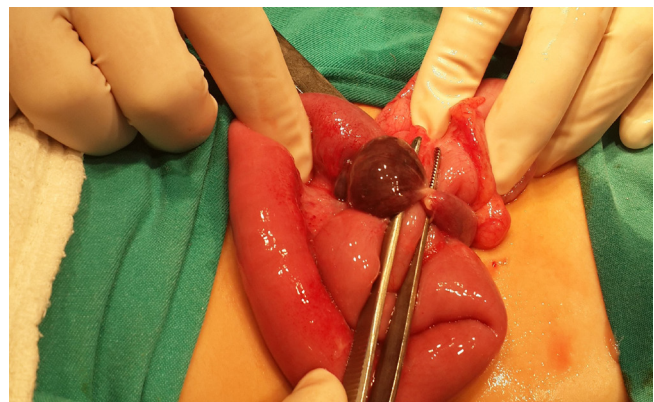


Figure 3. A black axially torsed necrotic Meckel's diverticulum (MD)

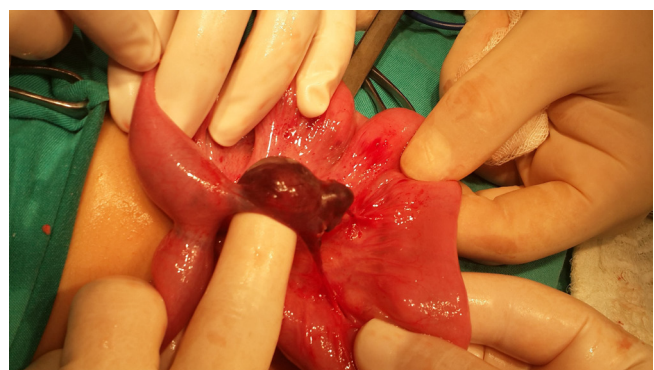

Figure 4. After untwisted Meckel's diverticulum (MD), there were two peritoneal bands which arise from its tip were attached to the mesentery of non adjacent small bowel.

mucosa was detected. Recovery was uneventful and the patient was discharged on the 7th postoperative day.

### Discussion

Axial torsion of MD is an unusual case presentation. Only 8 cases in children and approximately 20 cases in adults were found in the literature [3, 4, 10].

The etiology of axial torsion of MD remains unclear. It is reported that larger and longer MD and narrow diameter of the base are important factors that increase the risk for axial torsion. Associated neoplastic growth and inflammation of the diverticulum are reported as other predisposing factors. In some cases such as ours, attachment of the diverticulum to adjacent anatomic structures can cause axial torsion of MD [1, 3, 4]. However, it is reported that the majority of MD have a free end. In adults, most cases of twisted and gangrenous MD are related to fibrous fixed diverticulum, while in children, the reported cases of twisted MD have a free end [3]. But in our case, peritoneal bands that arose from the MD end to the mesentery of another small bowel were identified. This is the first case in which attachment of the diverticulum to adjacent anatomic structures was the cause of axial torsion of MD in a child.

Our patient presented with an initial onset of acute gastroenteritis. One similar pediatric case has been reported in the literature. But unlike our case, it had a free-ended MD [3]. In our case, peristaltic hypermotility may have caused herniation of the small bowel under the peritoneal band, resulting in axial torsion and necrosis of MD. Gastroenteritis can be complicated with an abdominal surgical emergency such as invagination, volvulus, and perforation. A case of gastroenteritis-complicated MD is extremely rare [3].

Diagnosis before surgery is difficult. The complicated MD has no specific value. Clinical findings and abdominal radiography are most important for the determination of surgical timing [1, 3, 4]. Abdominal ultrasound may rule out other abdominal surgical emergencies such as invagination. Sometimes MD can be identified as a tube-like, non-peristaltic structure. Other diagnostic techniques including <sup>99m</sup>Tc-pertechnetate scan, barium enema, and CT-scan images do not have a strong diagnostic value and correct preoperative diagnosis has been reported as 6-30% [1, 3, 4].

The treatment of symptomatic MD is surgical resection through laparoscopy or laparotomy. A wedge resection of MD is usually sufficient; occasionally some ileum segment resection and end-to-end anastomosis is necessary [1, 3-5, 9].

### Conclusion

We report a very rare form in a child of acute small bowel obstruction secondary to herniating of the portion of the terminal ileum under 2 peritoneal bands that arose from MD to the mesentery of non-adjacent small bowel; this caused axial rotation of MD, resulting in gangrene. The preoperative diagnosis is difficult. Early surgery is important for correct diagnosis and for preventing strangulation and gangrene of the bowel.

### Competing interests

The authors declare that they have no competing interests.

### References

1. Seth A, Seth J: Axial torsion as a rare and unusual complication of a Meckel's diverticulum: a case report and review of the literature. *J Med Case Rep* 2011;5:118.
2. Sancar S, Demirci H, Sayan A, Arıkan A, Candar A: Meckel's diverticulum: Ten years' experience. *Ulus Cerrahi Derg* 2015;1:65-7.
3. Tassinari D, Cimatti AG, Tani G, Lima M: A common case of gastroenteritis in a child followed by an axial torsion of Meckel diverticulum: a rare and unusual complication. *BMJ Case Rep* 2013; doi:10.1136/bcr-2012-006656.
4. Nose S, Okuyama H, Sasaki T, Nishimura M: Torsion of Meckel's Diverticulum in a Child. *Case Rep Gastroenterol* 2013;7:14-8.
5. Cartanese C, Petitti T, Marinelli E, Pignatelli A, Martignetti D, Zuccarino M, Ferruzzi L: Intestinal obstruction caused by torted gangrenous Meckel's diverticulum encircling terminal ileum. *World J Gastrointest Surg* 2011;3:106-9.
6. Akbulut S, Yagmur Y: Giant Meckel's diverticulum: An exceptional cause of intestinal obstruction. *World J Gastrointest Surg* 2014;6:47-50.
7. Singh Gupta S, Singh O: Loop formation of Meckel's diverticulum causing small bowel obstruction in adults: report of two cases. *Ulus Travma Acil Cerrahi Derg* 2011;17:567-9.
8. Murruste M, Rajaste G, Kase K: Torsion of Meckel's diverticulum as a cause of small bowel obstruction: A case report. *World J Gastrointest Surg* 2014;6:204-7.
9. Sasikumar K, Noonavath RN, Sreenath GS, Maraju NK: Axial Torsion of Gangrenous Meckel's Diverticulum Causing Small Bowel Obstruction. *J Surg Tech Case Rep* 2013;5:103-5.
10. Lambropoulos V, Papageorgiou I, Kepertis C, Sfoungaris D, Spyridakis I: Uncommon Surgical Causes Of Right Lower Quadrant Pain In Children. *Single Center Experience. J Clin Diagn Res* 2015;9:1

### How to cite this article:

Suzen A, Erturk N, Topal Y. Gangrene of Meckel's Diverticulum Secondary to Axial Torsion in a Child: An Unusual Complication. *J Clin Anal Med* 2016;7(5): 717-9.